



## Case Report / Olgu Sunumu

# Titanium elastic nail treatment for a humeral shaft fracture of an adolescent arm wrestler: A case report and literature review

## Adölesanda bilek güreşi sırasında ortaya çıkan humerus shaft kırığının titanyum elastik çivi ile tedavisi: Olgu sunumu ve literatür incelemesi

Yavuz Şahbat<sup>1</sup> , İsmail Murad Pepe<sup>2</sup> 

<sup>1</sup>Department of Orthopaedics and Traumatology, Maresal Çakmak State Hospital, Erzurum, Turkey

<sup>2</sup>Department of Orthopaedics and Traumatology, Antalya Bilim University, Faculty of Health Science, Antalya, Turkey

### ABSTRACT

Arm wrestling is a sport where two people take opposing positions at a table and put their elbows on the table with their palms together, the aim being to make the opponent's hand touch the table. Arm wrestling, which seems harmless, may become a show of strength for adolescents and young adults. Muscle and tendon injuries and bone fractures may occur due to arm wrestling. Fractures of the humeral shaft and distal third region can also occur due to arm wrestling. Here, we present the contribution of closed reduction and titanium intramedullary nail treatment to early return to school for a 14-year-old male patient with an AO 12.A1 fracture of the humeral shaft that occurred during arm wrestling. Our treatment reduced the duration of immobilization, provided complete union at the fracture site along with full range of motion of shoulder and elbow joints at 3 months after the injury.

**Keywords:** Titanium elastic nail, humeral shaft fracture, arm wrestling

### ÖZ

Bilek güreşi iki kişinin bir masa üzerinde karşılıklı pozisyon alarak dirseklerini masaya koyup avuçlarını birleştirdiği ve amacın rakibin elini masaya değdirmeyi amaçlayan spordur. Zararsız gibi görünen bilek güreşi adölesan ve genç erişkinler için güç gösterisi olabilmektedir. Bilek güreşine bağlı kas, tendon yaralanmaları ve kemik kırıkları gerçekleşebilmektedir. Humerus shaft ve distal 1/3 bölgesinin kırıkları bilek güreşi sonrası gelişebilmektedir. 14 yaşındaki erkek hastanın bilek güreşi sırasında humerus shaft AO 12.A1 kırığının kapalı redüksiyon ve titanyum intramedüller çivi ile tedavisinin okula erken dönüşe katkısını sunmaktayız. Tedavi seçeneğimiz immobilizasyon süresini kısaltarak yaralanmadan 3 ay sonra tam kaynama ve tam omuz ve dirsek eklem hareketi sağlamıştır.

**Anahtar Sözcükler:** Titanyum elastik çivi, humerus shaft kırığı, bilek güreşi

### INTRODUCTION

Arm wrestling is a sport where two people take opposing positions at a table or a bar and put their elbows on the table with their palms together, the aim being to make the opponent's hand touch the table. This sport exhibits a show of strength for adolescents and young adults. It is popular for young adults because the rules are simple and no equipment is required (1).

This seemingly harmless competition exerts high rotational force on upper extremity. It can cause various problems ranging from simple tendinitis to muscle, joint, connective tissue, and nerve injuries and various fractures (2). OTA 12.A1 and 12.B1 fractures of the humeral shaft are known as fractures directly related to arm wrestling (3). Such cases are frequently seen in the age group of 20-50 years. Many different types of injuries such as humeral shaft fractures, medial epicondyle fractures, forearm fractures, scapula

fractures, radial head fractures, and ligament and tendon injuries have been reported among patients in different age groups (2, 4-7).

Our case report presents the titanium elastic nail (TEN) technique, which allows for early mobilization and a sooner-than-expected return to school after a spiral oblique humeral shaft fracture due to arm wrestling.

### CASE REPORT

The 14-year-old male patient presented to the emergency department with the complaint of pain in the right arm that originated while arm wrestling (or Indian wrestling) at school. When the patient, who had no known hereditary diseases, was evaluated in the emergency department. The patient had pain with minimal movement in his elbow.

Received / Geliş: 22.08.2022 · Accepted / Kabul: 31.10.2022 · Published / Yayın Tarihi: 12.02.2023

Correspondence / Yazışma: Yavuz Şahbat · Maresal Fevzi Çakmak Şehir Hastanesi, Ortopedi ve Travmatoloji Kliniği, Erzurum, Türkiye · yavuzsahbat@gmail.com

Cite this article as: Sahbat Y, Pepe IM. Titanium elastic nail treatment for a humeral shaft fracture of an adolescent arm wrestler: A case report and literature review. *Turk J Sports Med.* 2023 58(1):42-6; <https://doi.org/10.47447/tjism.0715>

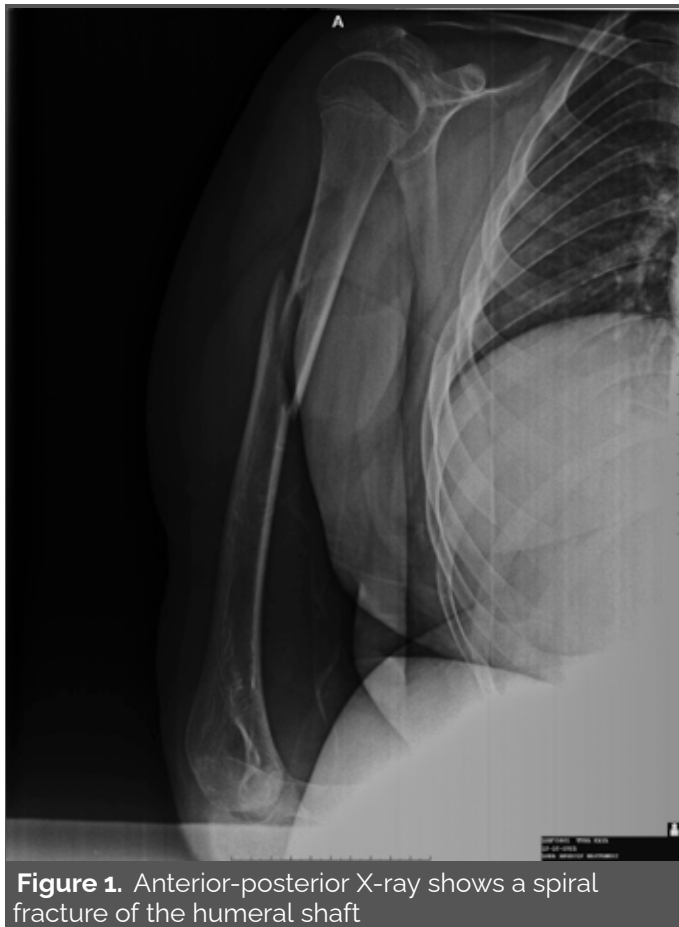
© 2023 Turkish Sports Medicine Association. All rights reserved.

This is an open access article under the terms of the Creative Commons Attribution-NonCommercial License, which permits use, distribution and reproduction in any medium, provided the original work is properly cited and is not used for commercial purposes (<http://creativecommons.org/licenses/by-nc/4.0/>).

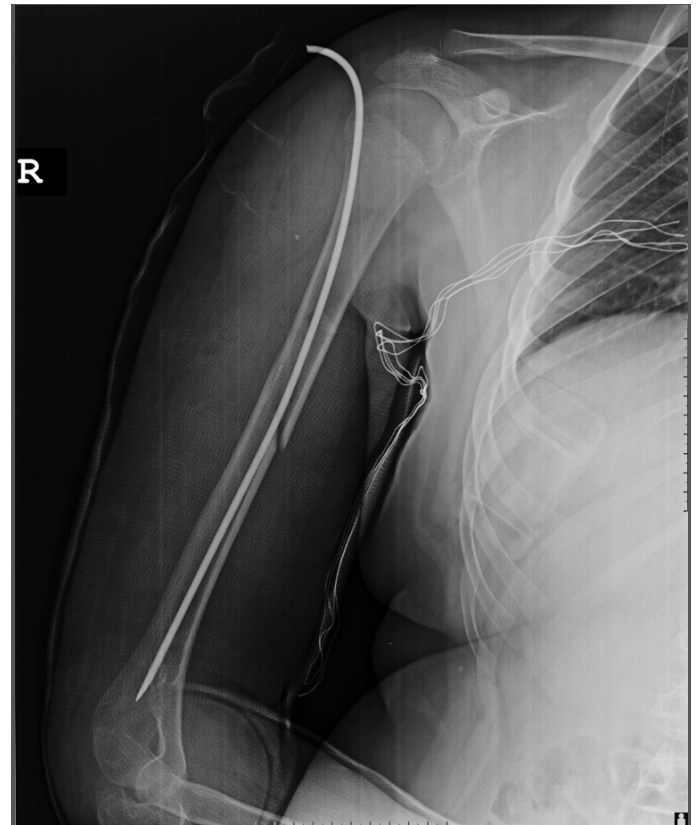
In the initial evaluation, motor examination of the wrist and finger, motor and sensory examination of the median, ulnar, radial, and musculocutaneous nerves were found intact. The patient had pain in forearm supination and pronation movements, as well as pain in elbow joint movements without restriction. The patient, who was 180 cm tall and weighed 86 kg (body mass index: 26.5), with right arm dominance.

Compartment syndrome was not considered for the patient, who had diffuse skin edema of the arm. The patient was evaluated by standard anterior-posterior plane X-Ray.

An AO (OTA) 12.A1 humeral diaphyseal fracture (Figure 1) was observed via anterior-posterior and lateral X-Ray. Patient was treated with a U-slab/U-splint and rotation of the U-splint was pursued as conservative treatment. The patient's family stated that since the injury coincided with the boy's exam week, prolonged limitation of his active limb would negatively affect his educational success. Titanium elastic nail treatment with fluoroscopically controlled closed reduction was accordingly planned.

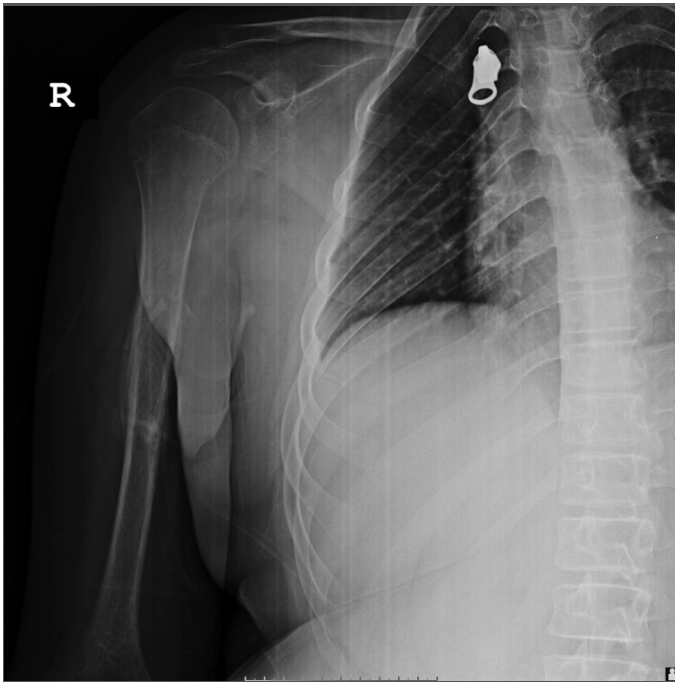


The fracture was treated with closed reduction and one elastic nail of 3.5 mm was applied to protect the epiphysis over the tuberculum majus with a 2-cm incision (Figure 2). Special attention was paid to ensure that the elastic nail did not cross the proximal epiphysis. A U-splint was also applied in the same treatment session.

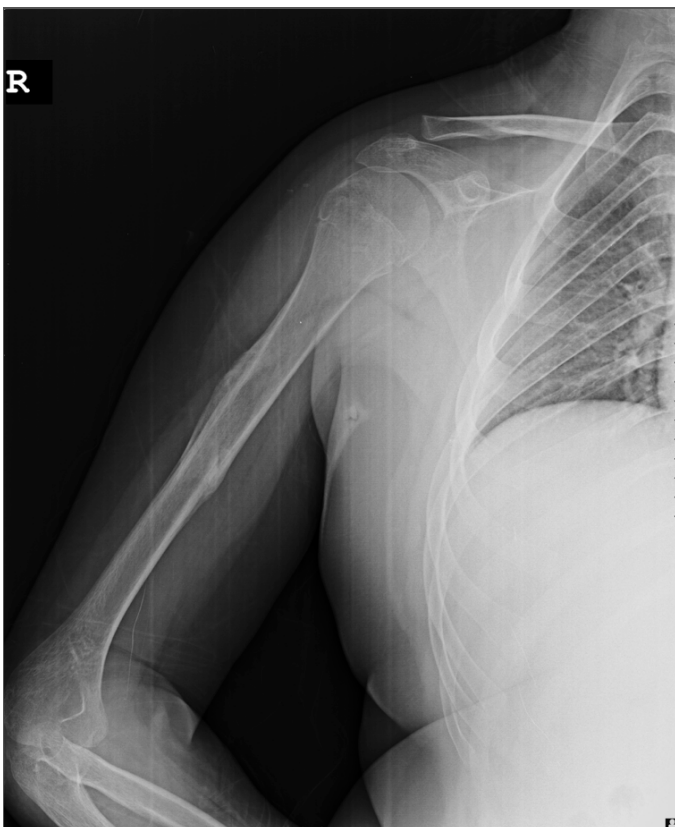

Union was detected in the third week after the operation, with X-Ray controls being performed in the first and third weeks after surgery. TEN was removed and a Sarmiento splint was applied to enable shoulder-elbow joint movement (Figure 3).

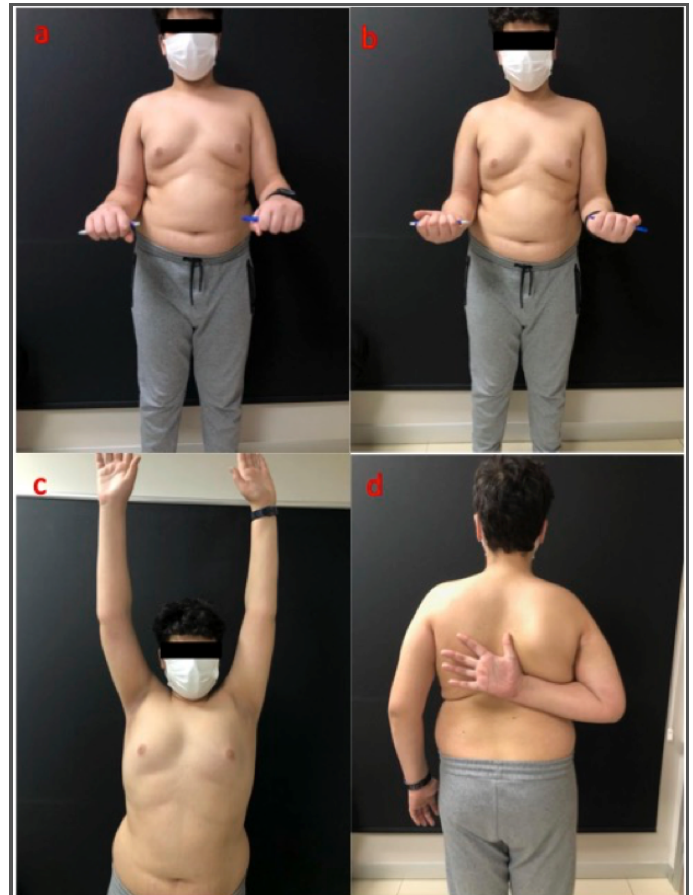The Sarmiento splint was removed after 3 weeks. Union was observed at 6 weeks and there was no pain during elbow joint motion (Figure 4). Shoulder and elbow joint motion were uninhibited, and complete union was achieved after 3 months (Figure 5).



**Figure 3.** Early callus formation after removal of the titanium elastic nail at the third post-operative week.



**Figure 4.** X-ray of mature callus tissue after removal of the Sarmiento brace at 6 months after the operation.



**Figure 5.** Clinical imaging of the patient at 3 months after surgery. A and B: Full range of motion of pronation and supination; C: Full shoulder abduction; D: Full range of motion of shoulder internal rotation and elbow flexion

## DISCUSSION

Most humeral fractures occur with direct trauma (8). There are also cases of indirect fractures in which direct trauma is not effective in the mechanism. Indirect fractures may occur in oncological patients and patients with metabolic bone diseases, but can also develop as a result of sudden muscle contraction. A few examples of indirect fractures resulted from sudden muscle contraction were reported among baseball players, grenade throwers, and arm wrestlers (4, 9). Medial epicondyle fractures in the adolescent age group due to arm wrestling have been reported; however, no humeral shaft fractures have been presented to date (2). Citak et al. presented a 24-year-old patient as the youngest patient in the literature (4). Subsequently, Kim et al. presented a 20-year-old patient, while Frankowska et al. reported a 19-year-old patient and Karadeniz et al. reported a 16-year-old patient. Thus, our report, to the best of our knowledge, presents the youngest patient in the literature to date (9-12).

Although some authors argue that the players' position; whether sitting or standing, may increase the risk for frac-

ture, the literature asserts that neither the position of the players nor the stage of the match make a difference (3, 5, 13). Arm wrestlers should be aware of this complication and should seek appropriate guidance to reduce the risk of humeral shaft fractures (13). Our patient was only 14 years old, much younger than people who pursue this sport professionally.

The possible mechanism of humeral fractures during arm wrestling has been discussed before by other authors (1, 3, 5). The elbow joint is fixed in flexion by the biceps and the brachialis muscle, and the shoulder joint is actively forced into internal rotation against the force created by the pectoralis major, subscapularis, and teres major muscles. These forces result in strong torque along the humeral shaft and can result in spiral fractures. Furthermore, only the rotator force applied on the humerus causes spiral fractures, while axial load and rotator force can cause butterfly fragment fractures (3). Our patient had a spiral fracture. Karadeniz et al. reported that their entire series of 19 cases had distal 1/3 fractures (10). However, we believe that the probable reason for the fracture in our case, being located proximally to the humeral shaft, was his young age as well as his position while arm wrestling.

Spiral fractures of the distal humerus, also known as Holstein-Lewis fractures, are typical for this sport (14). Holstein-Lewis fractures pose particular risk for the radial nerve. Radial nerve damage has been reported in 22-31% of the injuries attributed to Holstein-Lewis fractures in the literature (9, 15). The radial nerve may be damaged due to direct neuropraxial effects of the rotation force or injury caused by fracture fragments. Karadeniz et al. reported that 22% of their patients had radial nerve injury findings at first admission; however, at 6 months of follow-up at latest, none of their patients had any residual radial nerve signs (10). We concluded that our patient was free of such risk, since his injury occurred in the proximal part of the humeral shaft.

Treatment options include: closed reduction and cast-splint immobilization, open reduction and TEN, open reduction and plate osteosynthesis. TEN can be used in adolescent and adult humeral shaft fractures. Pogorelić et al. reported that TEN method is an effective method for the operative stabilization of humeral fractures of pediatric patients due to excellent functional and clinical results and low complication rate (16). Because our patient was a high BMI adolescent currently enrolled in school, we preferred closed reduction and TEN (2). We assumed that long-term active limb restriction could negatively affect his education. Through implementation of this technique the immobilization duration was reduced from 6 weeks to 3 weeks. The current

study is the first in the literature to present the use of TEN for humeral fractures after arm wrestling. Our goal was to have our patient return to his educational life as quickly as possible. Karadeniz et al. also recommends surgery for a faster recovery, as this would both ensure the patient's return to work as soon as possible and less disruption in social activity (10).

Mayfield et al. stated that humerus spiral fractures after arm wrestling achieved earlier union than those in the same region developed by another mechanism. The bone quality and union capacity of the adult athletes in their study sample were better (8). Some authors have argued that the union occurs in weeks 12 or 13 (7, 8, 10). We believe that the complete union with full shoulder and elbow joint movement achieved for our patient in the 6th week were due to both this early union mechanism and the fact that the patient was still an adolescent.

Kim et al. conducted a research among Korean soldiers, and reported the highest number of such patients in the literature to date. Although more injuries of the dominant arm have been reported previously in the literature (10, 13, no arm dominance was observed by Kim et al. (9). Our patient also developed a dominant-side fracture. We suggested that this was due to the fact that professional arm wrestlers could compete with both arms, while amateurs were competing with only the dominant arm.

In conclusion, our patient is the youngest patient to our knowledge with a humeral shaft fracture due to arm wrestling. We found that treatment with closed reduction and titanium nails for adolescent patients provides quicker return to sports and school.

#### **Conflict of Interest / Çıkar Çatışması**

The authors declared no conflicts of interest with respect to authorship and/or publication of the article.

#### **Financial Disclosure / Finansal Destek**

The authors received no financial support for the research and/or publication of this article.

#### **Author Contributions / Yazar Katkıları**

Concept: YŞ; Design: YŞ, İMP; Supervision: İMP; Materials: İMP; Data Collection and/or Processing: İMP; Analysis and Interpretation: YŞ, İMP; Literature Review: YŞ; Writing Manuscript: YŞ, İMP; Critical Reviews: YŞ, İMP

## **REFERENCES**

1. CHAO SL, Miller M, TENG SW. A mechanism of spiral fracture of the humerus: a report of 129 cases following the throwing of hand grenades. *J Trauma*. 1971;11(7):602-5.
2. Moloney DP, Feeley I, Hughes AJ, Merghani K, Sheehan E, Kennedy M. Injuries associated with arm wrestling: A narrative review. *J Clin Orthop Trauma*. 2021;18:30-7.
3. Kruczyński J, Nowicki JJ, Topoliński T, Srokowski G, Mańko G, Chantsoulis M, et al. Radiological and biomechanical analysis of humeral fractures occurring during arm wrestling. *Med Sci Monit*. 2012;18(5):CR303-7.
4. Citak M, Backhaus M, Seybold D, Muhr G, Roetman B. Arm wrestling injuries--report on 11 cases with different injuries. *Sportverletz Sportschaden*. 2010;24(2):107-10.

5. Ogawa K, Ui M. Fracture-separation of the medial humeral epicondyle caused by arm wrestling. *J Trauma*. 1996;41(3):494-7.
6. Considine S, Hirpara K, Hynes D. Fracture of the scapular neck sustained in an arm wrestling match. *Ir Med J*. 2014;107(9):298-9.
7. Fallis G, Ferguson K, Malcolm B. An unusual fracture in arm wrestling. *Phys Sportsmed*. 1990;18(4):93-6.
8. Mayfield CK, Egol KA. Humeral fractures sustained during arm wrestling: a retrospective cohort analysis and review of the literature. *Orthopedics*. 2018;41(2):e207-e210.
9. Kim K-E, Kim E, Park J, Kim S, Kwon J, Moon G. Humeral shaft fracture and radial nerve palsy in Korean soldiers: focus on arm wrestling related injury. *BMJ Mil Health*. 2021;167(2):80-3.
10. Karadeniz E, Demiroz S, Oktem F, Memisoglu K, Kesemenli CC. Humeral fractures sustained during arm wrestling. *Eur J Trauma Emerg Surg*. 2022;48(4):3109-14.
11. Frankowska-Rutkowska M, Górska J, Jedwabiński M, Mańkowski D, Maciejewski M. Fracture of the humerus during arm wrestling: report on 9 cases and review of the literature. *Med Biol Sci*. 2013;27(3):36-8.
12. Correia RF, Ribeiro AN, de Araújo RP. Arm-wrestling injuries—A systematic review of the medical literature. *MTB&RehabJournal*. 2017;16:567.
13. Pande K, Nishat N, Afzal S, Ishak L. Humeral shaft fracture sustained during arm wrestling with review of factors contributing to its causation. *Malays Orthop J*. 2021;15(3):15-20.
14. Holstein A, Lewis G. Fractures of the humerus with radial-nerve paralysis. *J Bone Joint Surg Am*. 1963;45:1382-88.
15. Ekholm R, Ponzer S, Törnkvist H, Adami J, Tidermark J. The Holstein-Lewis humeral shaft fracture: aspects of radial nerve injury, primary treatment, and outcome. *J Orthop Trauma*. 2008;22(10):693-7.
16. Pogorelić, Z., Kadić, S., Milunović, K. P., Pintarić, I., Jukić, M., & Furlan, D. Flexible intramedullary nailing for treatment of proximal humeral and humeral shaft fractures in children: A retrospective series of 118 cases. *Orthop Traumatol Surg Res*. 2017;103(5):765-70.